



A Novel Solution to Securing Nasogastric Feeding Tubes in Pediatric Burn Patients

Alyssa Brzenski¹, Bruce Potenza², Jeanne Lee² and Mark Greenberg^{1*}

¹University of California, San Diego, Department of Anesthesiology, 200 West Arbor Dr, San Diego Ca 92103, United States.

²University of California, San Diego, Department of Surgery, 200 West Arbor Dr, San Diego Ca 92103, United States.

Authors' contributions

This work was carried out in collaboration between all authors. All authors were involved in the design of the procedure and the implementation of this new procedure. Authors MG and AB wrote the first draft of the manuscript. Author AB managed the literature searches. All authors read and approved the final manuscript.

Article Information

DOI: 10.9734/BJMMR/2015/13729

Editor(s):

- (1) Shashank Kumar, Department of Biochemistry, University of Allahabad, Allahabad, India.
(2) Jimmy T. Efid, Department of Public Health, Director of Epidemiology and Outcomes Research East Carolina Heart Institute, Brody School of Medicine, Greenville, North Carolina, USA.

Reviewers:

- (1) Anonymous, Universidade Federal do Rio Grande do Sul, Brazil.
(2) Rakesh Garg, Department of Anaesthesiology and Intensive Care, All India Institute of Medical Sciences, New Delhi, India.
Complete Peer review History: <http://www.sciencedomain.org/review-history.php?id=716&id=12&aid=6713>

Method Article

Received 31st August 2014
Accepted 11th October 2014
Published 29th October 2014

ABSTRACT

Aims: To present a novel method of securing nasogastric (NGT) feeding tubes in pediatric burn patients.

Presentation of Case: We have developed an arrangement of tube, twill tie and suture, to secure a feeding tube in position, in which a twill tie is secured around the patient's head and interwoven into the burn dressing. The NGT is secured to the twill tie via a locking suture.

Discussion: Nasogastric feeding tubes are important in pediatric burn patients to facilitate the healing process by meeting their increased metabolic demand for protein and calories. These tubes are typically secured via tape to the face, but in patients with facial burns tape may not adequately anchor the feeding tube, allowing for unintended dislodgement of the NGT. Inadvertent removal of nasogastric tubes places patients at risk for complications including prolonged healing time and aspiration, as well as the need for replacement of the NGT.

*Corresponding author: Email: mgreenberg@ucsd.edu;

Conclusion: We present a novel method of securing nasogastric feeding tubes in pediatric burn patients, which has decreased the inadvertent dislodgement of NGTs in the pediatric burn patients.

Keywords: Nasogastric tube; burns; aspiration.

1. INTRODUCTION

Burn patients are often dependent on feeding tubes for adequate nourishment, due to increased metabolic demand for protein and calories. Many patients are either unable, or uninterested, in taking in these nutrients orally. Burn patients who receive enteral nutritional supplementation via a nasogastric tube have lower mortality and shorter healing times [1,2] than those who receive supplementation via a parenteral route. Nasogastric (NGT) feeding tubes are most commonly secured to the face using tape. However, in patients who have facial burns, tape may not stick to the underlying burned tissue, necessitating tying the tube with twill ties (Fig. 1).

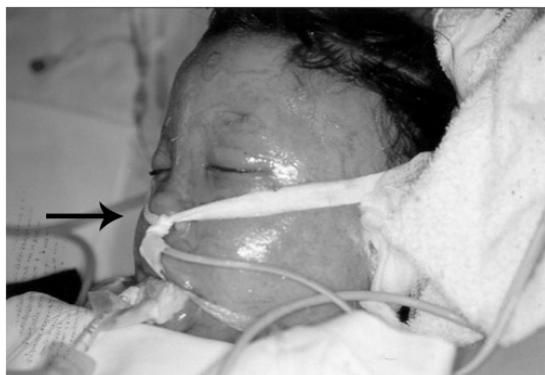

Fig. 1. Twill tie securing a nasogastric tube

Securing small 8 french feeding tubes using twill is problematic due to slippage of the tie on the tube. It is also difficult to get a secure, tight fit of the twill around the head leading to frequent tube movement or patient removal of the enteric tube in as many as 28.9% of cases [3]. Thus, even if the distal location of a feeding tube was confirmed radiographically, failure of the twill to hold the tube in proper position is a frequent problem, leading to additional radiologic studies, and potentially pulmonary aspiration of the feeds if the tube lies in the posterior pharynx or proximal esophagus. Repeated replacement of nasogastric tubes places the patient at risk for complications such as inadvertent tracheal intubation [4] and pneumothorax [5,6]. Difficulty securing an NG tube was a frequent problem in our Burn Intensive Care Unit, leading us to a

search for a more secure method to hold these tubes in place.

2. PRESENTATION OF CASE

We have developed the following arrangement of tube, twill and suture, to secure a feeding tube in position (Figs. 2a-c). After changing the patients bandages, a twill tie, is measured to fit around the patient's head with enough extra length to be securely tied. The twill tie is then woven in to the burn netting to hold the twill in position, preventing movement in a superior/inferior direction (Fig. 2a).

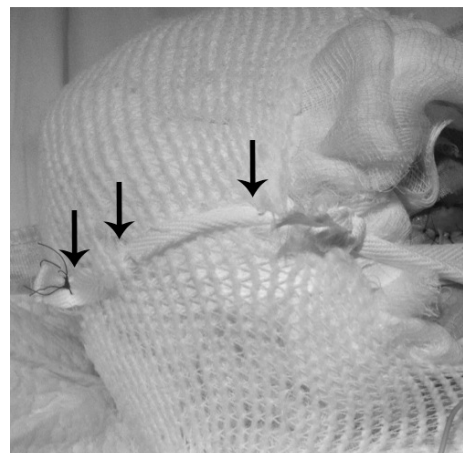


Fig. 2a. Twill tie secured to the patient by weaving the tie into the burn netting

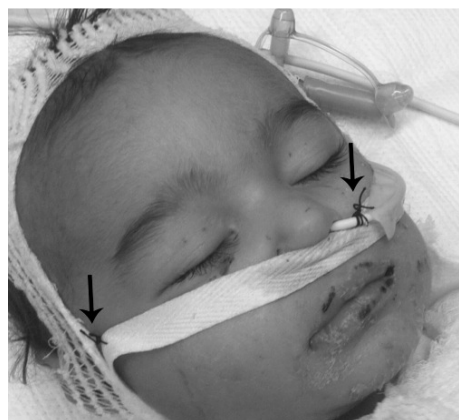

Fig. 2b. Sutures placed to secure NGT to the twill tie and the twill tie to the burn netting

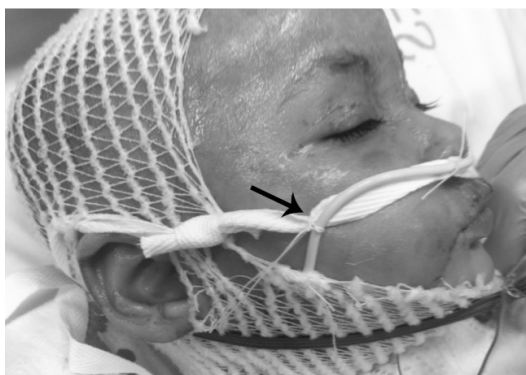

Fig. 2c. An additional suture can be placed to further secure the NGT to the twill tie

If necessary, a suture can be put in the place where the twill initially inserts into the burn net (Fig. 2b). The twill tie is then tied to give a snug fit around the philtrum. To secure the twill to the NG tube, a locking suture is placed around the feeding tube, in a snug, but not constricting or occlusive manner, making sure the tie is tight enough that the tube doesn't move (Fig. 2b). Once the suture is tied, place the needle through the twill and tie the knot tight. This procedure will keep the feeding tube secured to the twill and the twill from moving around the head. If needed, additional sutures can be placed from the twill to the feeding tube proximal to the initial site, for extra security (Fig. 2c).

We often tape the tube to the twill to keep it from moving around. The key feature of this technique is to make sure to weave the twill using gentle puncture of the burn netting as this prevents movement of the twill on the head. Clearly this method is not failsafe, and the child or caretakers can still dislodge the tube, making vigilance essential to prevent complications from feeding with a malpositioned tube. This technique can also be used in a similar fashion to secure an endotracheal tube to a patient with facial burns. One important issue is that one must take extreme care to monitor the position of the tube during dressing changes, as the tie will no longer be snugly fit. Since we do all dressing changes under general anesthesia this can be easily monitored, but we caution to use extreme care when removing the dressing to make sure the tube does not get pulled out when the burn netting is removed.

3. DISCUSSION

Enteric feeds, via NGT, are the most common means to meet the increased nutritional needs of

pediatric burn patients. Accidental dislodgement of the NGT by the patient himself or during routine care of the patient increases the risk of complications. These complications can be minimized by adequately securing the NGT.

There are multiple different methods to secure enteric feeding tubes. The easiest and most frequent method for securing these tubes is with tape. The tape can be secured to the nose or the upper lip. However, in patients with facial burns this method does not secure the NGT well due to the non-intact skin. In patients at high risk for NGT removal, such as agitated patients, or in whom the NGT is critical, such as ear nose and throat patients following large head and neck resections, an anterior septal suture or a bridle apparatus [7] are frequently used to secure NGT. A bridle apparatus can withstand double the force [8] compared to an anterior septal suture to prevent patient removal. This bridle apparatus in adults has a clinically significant lower rate of unintentional dislodgement and longer time until failure of the NGT [9]. The bridle technique utilizes a soft catheter looped around the nasal septum to secure the NGT. There is a potential risk of external nasal ulcerations, epistaxis and sinusitis utilizing the bridle method. The new technique that we describe avoids these risks given that there are no additional foreign bodies introduced into the nasal cavity. We have also used this technique in adults and to secure endotracheal tubes as well. Future studies will be needed to examine the failure rate with this new technique.

Burn patients are at risk for developing cellulitis and nosocomial infections during their hospitalization. Adequate nutrition places the patient at a better advantage to adequately prevent any such infections. However, introduction of any foreign body presents the possibility that a nosocomial infection could be caused. The enteric feeding tubes, twill and suture are not sterile. Although the enteric feeding tubes are not being placed into a sterile environment, we attempt to minimize the introduction of bacterial by placing the NGT only once. In addition, by not securing the NGT to the face our technique avoids the potential for tearing any intact skin as well as potentially decreasing sinusitis by avoiding a bridle apparatus or an anterior septal suture.

4. CONCLUSION

Securing an NGT in pediatric burn patients with facial burns using twill integrated into the burn

netting, fastened with suture is a novel method to keep these vital feeding tubes in place. This method can also be used in adults, or to secure endotracheal tubes as well. Future studies should be completed to assess the failure rate as well as the rate of complications of this new technique.

CONSENT

The author's Institutional Review Board does not require consent for this type of publication.

ETHICAL APPROVAL

Not applicable.

COMPETING INTERESTS

Authors have declared that no competing interests exist.

REFERENCES

1. Lam NM, Tien NG, Khoa CM. Early enteral feeding for burned patients-an effective method which should be encouraged in developing countries. *Burns*. 2008;34:192-6.
2. Marik PE, Zaloga GP. Early enteral nutrition in acutely ill patients: A systemic review. *Crit Care Med*. 2001;29(12):2264-70.
3. Mion LC, Minnick AF, Leipzig R, Catrambone CD, Johnson ME. Patient-initiated device removal in intensive care units: A national prevalence study. *Crit Care Med*. 2007;35(12):2714-20.
4. Araujo-Preza CE, et al. Use of capnometry to verify feeding tube placement. *Crit Care Med*. 2002;30:2255-9.
5. Saltzberg DM, Goldstein M, Levine GM. Feeding tube-induced pneumothorax. *JPEN J Parenter Enteral Nut*. 1984;8:714-6.
6. Roubenoff R, Ravich EJ. Pneumothorax due to nasogastric feeding tubes. Report of four cases, review of the literature, and recommendations for prevention. *Arch Intern Med*. 1989;149:184-8.
7. Taams MA, Thomson SR, Hadley GP. Naso-enteral fine-bore feeding tube fixation in the burned child: an audit of a technique. *Pediatric Surgery International*. 1993;8(3):274-276.
8. Al-Hussaini A, Carey M, Sanu A. Head and neck surgical patients; is it time for a bridle era? *Eur Arch Otorinolaryngol*. 2014;271:1321-5.
9. Brugnolli A, et al. Securing of naso-gastric tubes in adult patients: A review. *International Journal of Nursing Studies*. 2014;51:943-50.

© 2015 Brzenski et al.; This is an Open Access article distributed under the terms of the Creative Commons Attribution License (<http://creativecommons.org/licenses/by/4.0>), which permits unrestricted use, distribution, and reproduction in any medium, provided the original work is properly cited.

Peer-review history:

The peer review history for this paper can be accessed here:
<http://www.sciencedomain.org/review-history.php?iid=716&id=12&aid=6713>