



Comparison between Conventional 2.0 mm Miniplates versus 3-D Plates In Management of Mandibular Fractures

**Meena Kumari¹, Kashif Ali Channar¹, Suneel Kumar Punjabi¹,
Mahwish Memon², Salman Shams^{1*} and Syed Ghazanfar Hassan¹**

¹Oral and Maxillofacial Surgery Department, Faculty of Dentistry, Liaquat University of Medical and Health Sciences, Pakistan.

²Operative Dentistry Department, Faculty of Dentistry, Liaquat University of Medical and Health Sciences, Pakistan.

Authors' contributions

This work was carried out in collaboration among all authors. Authors MK and SKP designed the study and performed the statistical analysis. Author SS wrote the protocol and wrote the first draft of the manuscript. Authors MM and SGH managed the analyses of the study. Author KAC managed the literature searches. All authors read and approved the final manuscript.

Article Information

DOI: 10.9734/JPRI/2020/v32i3731006

Editor(s):

(1) Dr. Rafik Karaman, Al-Quds University, Palestine.

Reviewers:

(1) Alireza Parhiz, Tehran University of Medical Science, Iran.

(2) Venkatesh Balaji Hange, K. D. Dental College & Hospital, India.

Complete Peer review History: <http://www.sdiarticle4.com/review-history/63824>

Original Research Article

Received 05 October 2020
Accepted 10 December 2020
Published 30 December 2020

ABSTRACT

Objective: To compare the outcomes stability, malunion and intra operative time by using 2.0mm conventional miniplates and 3-D plates in management of the anterior mandibular fracture.

Materials and Methods: Total 94 patients were included and equally divided in two groups. Fixation of fracture was done by 2.0mm conventional miniplates in Group-A and a single 3D plate in Group-B. Stability, healing and malunion were assessed on follow-up at 1st week, 6th week, and 12th week using Chi Square Test.

Results: Stability was 91.5% in group-A and 93.6% in group-B. Clinically malunion was 12.8% at 1st week, 14.8% at 2nd week, 14.8% at 8th week in group-A while in group-B, malunion was 8.5% at 1st week, 2nd week and at 8th week. Radiographically, malunion was 12.8% at 1st week, 14.8% at 2nd week, 14.8% at 8th week in group-A while in group-B, malunion was 8.5% at 1stweek, 2nd week and at 8th week.

Conclusion: The results of the study concluded that 3-D plating system has advantages over conventional 2 mm miniplates.

*Corresponding author: E-mail: salman_omfs@hotmail.com;

Keywords: *Stability; malunion; intra operative time; 2.0 mm conventional miniplates; 3-D plates; anterior mandibular fracture.*

1. INTRODUCTION

Injuries related to maxillofacial fractures are most probably traumatic in nature, and those are maxillofacial surgeons who treat them well. Literature says the most universal etiological factor related to maxillofacial injuries is road traffic accident (RTA) which shows around 45.3% involvement [1]. Causes other than RTA include falls (42.6%), assaults (0.89%), sport injuries (2.2%), and gunshot wounds (0.89%) [2]. As the mandible shows more central position of face and secondly due to its obvious prominence it gets fractured more often [3]. When it comes to RTA as causative factor, after zygomatico-maxillary complex fracture, the mandibular fracture is the subsequently occurring maxillofacial injury [4]. Mandible is the only freely moveable bone in the facial skeleton, because this bone has shown complex architecture that includes articulation with base of cranium. Because of cherished link with muscles of face, it has always shown strong biomechanical distraction [5]. The incidence of mandibular fracture like condyle 15.27%, coronoid 1.38%, angle 16.66%, body 18.75%, ramus 2.77%, symphysis 12.50% and parasymphysis exhibited the highest incidence 32.63%.

The modalities for the handling or managing fractures of the mandible have been in a constant state of development [5]. As according to Champy's law or principle, the rigid and semi rigid fixation technique with miniplating system have gained popularity as a treatment option, but there have been various and numerous management modalities over the years that include splinting of dentoalveolar injuries, circum-mandibular wiring, external pins, trans-osseous wiring etc [5,6]. The Champy's principles of osteosynthesis has stood the test of time and has proven to be the guiding line to established monocortical fixation the world wide choice for mandibular fractures management [6]. Rigid fixation technique by open reduction has various advantages when we compare it with close reduction technique. Noticeable gains of rigid fixation are short MMF period or even no MMF, mandibular function that gets early in incorporation, boost in patient happiness and quicker healing [7]. The main drawback in using routine miniplates technique is that it seems deficient in providing three dimensional stability of the fractured segment, and that too require

maxilla-mandibular fixation for a short period [2,4,8]. In recent years the most latest technique in treating maxilla-mandibular surgery is by the three dimensional (3-D) miniplates system, which is also a rigid fixation method [2].

To improve the surgical outcome of fixation with 3D plating system a continuous research is underway to spotlight the dimension, profile, number and mechanics of plate/screw systems [8]. Around 2 decades ago in 1993, a 3-D plate with quadrangular design by Farnad. He did it by uniting two miniplates with interlocking crossbars [2,9]. Stability by three dimensions was the basic concept thought in the development of 3-D plates [10]. And when it comes to stability, it is solely achieved by its configuration not by thickness or length [4,8,10,11]. Nowadays, 3D plate system is one the most standard alternate to conventional plating system, because it has advantage of providing concurrent in the tension and compression zones, and this property make the 3-D plate a time saving method too [8]. In treating maxillofacial trauma, we always desire a reduction method that provides a rapid bone healing and mechanical stability. To stabilize the fracture bone segments, the 3-D plating system requires less number of plates and screws as compared to conventional miniplates [12].

2. MATERIALS AND METHODS

This is a Comparative cross sectional study with non probability convenience sampling method, conducted at oral and maxillofacial surgery department of Liaquat University of Medical and Health Sciences Jamshoro, Hyderabad from September 2018 to August 2019. The Sample size was calculate by *Epi Tools* epidemiological www.epitools.ausvet.com.au/. The recommended sample size is 37 in each group, [9] to compensate the loss, we have added 10% for non responded, hence sample size is 47 in each group. Patients were divided by simple randomized method.

Group A: 2.0 mm mini plates (47patients)

Group B: 3-D plates (47patients)

2.1 Inclusion Criteria

- Either Gender.
- Age Group 18 to 50 years.

- Patients having clinical and radiographic evidence of isolated symphysis/parasympsis mandibular fracture.

2.2 Exclusion Criteria

- Patients not willing to participate in study
- Mentally retarded patients.
- Patient's with medically compromised for general anesthesia.
- Noncompliance patients.
- Edentulous Patient

2.3 Data Collection Procedure

Patients who fulfilled the inclusion criteria and gave written informed written consent for the study were enlisted for this study. Patients were recruited from Out Patient Department (OPD) or through emergency Department of Liaquat University of Medical & Health Sciences Jamshoro/ Hyderabad and were divided in to two group i.e. A and B group (by simple randomized method). Group A (2.0mm conventional miniplates) and Group B (3 D plates).

Diagnosis of mandibular fracture was made through clinical examination, Orthopantomogram (OPG) and P.A view of face and 3D CT scan where indicated.

Under general anesthesia after achieving maximum occlusion with maxillomandibular fixation, muco-periosteal flap was raised intra-orally and extra-orally (as per needed by case), after reduction the fracture was fixed with 2.0mm conventional miniplates in Group A and a single 3D plate in Group B (Moin International, Made in Pakistan) with screws of 6mm cortical/monocortical otherwise (as per needed by case). Standard IV antibiotics and analgesics were provided to patients of both group as immediate postoperative till 3days, followed by 5 days orally after discharge from hospital.

Stability and malunion were assessed clinically and by post-operative radiographs. The responses were recorded after the treatment of fractures and then at follow ups of patients which was at interval of 1st to 12th week

2.4 Data Analysis

The Data was analyzed by statistical software package SPSS version 20.0. The stability, malunion and intraoperative time were assessed by using "Chi Square Test" Qualitative variables

were expressed as frequencies and percentages. Descriptive variables like age, gender were calculated. P value less than 0.05 was considered statistically significant.

3. RESULTS

In group A there was 29(61.7%) male and 18(38.3%) female patients while in group B, there was 26(55.3%) male and 21(44.7%) female patients as presented in Table 1.

Table 1. Frequency distribution of gender (n=94)

	Group A n(%)	Group B n(%)
Male	29 (61.7)	26 (55.3)
Female	19 (38.3)	21 (44.7)
Total	47	47

The mean age of patients in group A and group B was 31.38±9.03 years and 30.10±9.35 years respectively. Frequency and percentage of age groups are presented in Fig. 1.

In group A, 22(46.8%) found with intra operative time<30 minutes and 25(53.2%) >30 minutes while in group B, 47(100%) were found with intra operative time<30 minutes as presented in Table 2.

Table 2. Frequency distribution of intraoperative time (n=94)

	Group A n(%)	Group B n(%)
<30 Min	22 (46.8)	47 (100)
>30 Min	25 (53.2)	0 (0)
Total	47	47

In our study, 43(91.5%) found with stability at immediate postoperative, same number of patients was found with stability at 1st week, 6th week and 12th week in group A while in group B, 44(93.6%) were found with stability at immediate postoperative, same number of patients was found with stability at 1st week, 6th week and 12th week.

Malunion was found at immediate postoperative (clinical occlusal discrepancies and radiographically step deformity) for 2(4.3%),

6(12.8%) at 1st week, 7 (14.8%) at 2nd week, 7 (14.8%) at 8th week in group A, while in group B, malunion was found for 4(8.5%) patient at immediate postoperative (clinical occlusal discrepancies), 1st week, 2nd week and at 8th week

Stratification with respect to treatment group was done to observe effect of these modifiers with

stability at 12th week, clinical malunion at 8th week and radiographically malunion at 8th week. The results showed that there was significant association of treatment group with clinical malunion at 8th week ($p=0.001$), radiographically malunion at 8th week ($p=0.001$) while no significant association was found with stability at 12th week ($p=0.694$) as presented in Table 3.

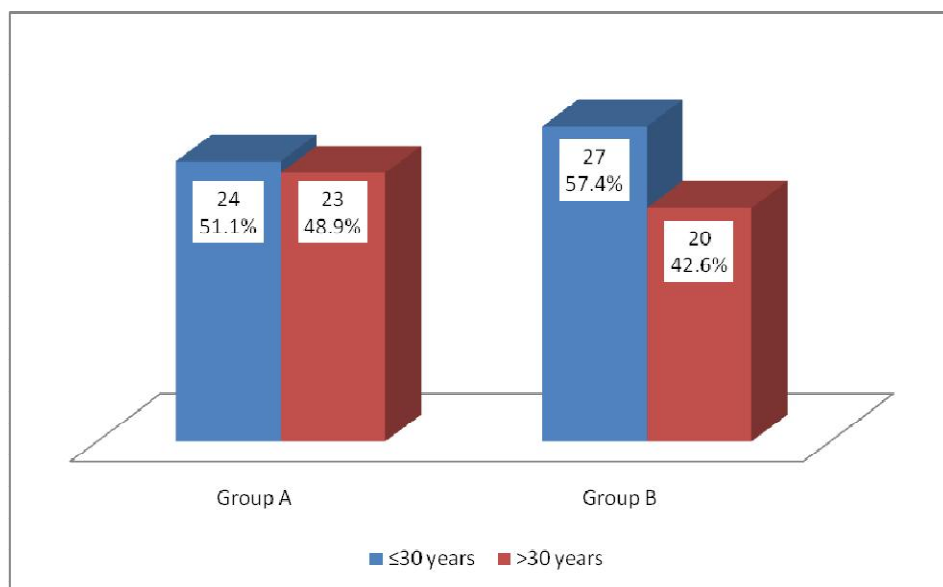


Fig. 1. Frequency and percentage of patients according to age group (N=94)

Table 3. Frequency and association of treatment group according to stability at 12th week, clinical malunion at 8th week, radiographically malunion at 8th week and intraoperative time (n=94)

Variable		Treatment Group		Total	P-Value
		Group A	Group B		
Stability At 12 th Week	Yes	43 (49.4)	44 (50.6)	87	0.694**
	No	4 (57.1)	3 (42.9)	7	
	Total	47	47	94	
Clinical Malunion At 8 th Week	Yes	7 (14.8)	4 (8.5)	11	0.001*
	No	40 (85.1)	43 (91.4)	83	
	Total	47	47	94	
Radiographically Malunion At 8 th Week	Yes	7 (14.8)	4 (8.5)	11	0.001*
	No	40 (85.1)	43 (91.4)	83	
	Total	47	47	94	
Total		47	47	94	

4. DISCUSSION

The main concept of 3-D plating system was initiated by Farmand. These plates derive their stability and mechanical properties because of their focused quadrangular profile, which is dependent on the principle of a quadrangular shape being a geometrically more stable design. It is specifically due to the shape of these plates on which stability and are dependent, rather than plate dimensions and thickness [13,14].

Findings of this study have shown that males were predominantly affected from anterior mandibular fractures as compared to females. Our data is widely supported by various similar studies performed in world like Zafar KJ [15] where he encountered 71.9% cases with male gender. Sadhwani BS [9] also showed male predominance with 64.29% cases. El Nakeeb [16] et al stated that Incidence in males compared with that of females was 4:1.

In this study the mean age of patients in group A and group B was 31.38 ± 9.03 years and 30.10 ± 9.35 years respectively. Data of this study in terms of mean age is widely supported by Zafar KJ where he reported mean age with 32.4. Gokkulakrishnan et al [17] showed in his study mean age of 30.9. One study carried out by Al-Tairi et al [18] came with mean age with less than 25 years i.e 24.5 years.

The operating time needed in group A (Conventional 2mm miniplate) was < 30minutes in 22(46.8) cases and >30 minutes in 25(53.2%) cases, while in group B all 47(100%) cases were found with intra operative time<30 minutes. According to the studies by Zafar KJ [15], Kumar [19], Kinra [20] and El Nakeeb [16] they also reported decreased operating with 3-D plates as compared to 2 conventional miniplates for the fixation of anterior mandibular fracture.

The initial biomechanical research on 3D plates was carried out by Farmand, and he establish that the constancy of 1 mm 3-D plate was comparable to the much thicker 2-0 mm miniplates (Steinhauser plate), which is intended for a single plate fixation of mandibular fractures. The final stability also appears to be compromised in Steinhauser's plate because of its deficient screw-bone interface [13]. In contrast our study showed no significant difference in terms of stability at 12th week follow up period in both groups.

In current study clinical and radiological malunion was found at the 8th week follow up was 14.8 % in group A and 8.5% in group B. Studies published by Kishor K [21] and Sadhwani BS [9] showed no case with malunion in both groups at the end of follow up period.

5. CONCLUSION

The results of the current study showed good stability, less procedure time required, less malunion with 3-D plating system. It can be concluded by the findings that 3-D plating system has advantages over conventional 2mm miniplates.

CONSENT AND ETHICAL APPROVAL

As per international standard or university standard written ethical approval has been collected and preserved by the author(s). Patients who fulfilled the inclusion criteria and gave written informed consent for the study were enlisted for this study.

COMPETING INTERESTS

Authors have declared that no competing interests exist.

REFERENCES

1. Harjani B, Singh RK, Pal US, Singh G. Locking v/s non-locking reconstruction plates in mandibular reconstruction. *Natl J Maxillofac Surg.* 2012;3:159-65.
2. Balkirshnan R, Ebenzer V, Dakir A. Three dimensional titanium mini plates in management of mandibular fractures. *Biomed and Pharmacol J.* 2014;7:241-46.
3. Rahpeyma A, Khajehahamdi A, Mehni SB. Treatment of mandibular fractures by two perpendicular mini plates. *Iranian J Otorhinolaryngo.* 2014;26:31-6.
4. Prasad R, Thangavelu K, John R. The role of 3D plating system in mandibular fractures: A prospective study. *J Pharm Bioall Sci.* 2013;5:10-13.
5. Arslan ED, Solakoglu AG, Komut E, Kavalci C, Yilmaz F, et al. Assesment of maxillofacial department in emergency department. *World J Emerg Surg.* 2014; 9:1-7.
6. Rai S, Rattan V. Current perspective in the management of mandibular fracture. *J Postgrad Med Edu Res.* 2014;48:63-7.

7. Yazdani J, Talesh KT, Motamedi MHK, Khorshidi R, Fekri S, et al. Mandibular angle fracture: Comparison of one miniplate v/s two miniplates. *Trauma Mon.* 2013;18:17-20.
8. Yadav S, Agarwal A, Singh S, Kumar S, Anand KR, Chhabra V. 3-D locking titanium miniplates in management of mandibular fracture: A prospective clinical study. *J Dent Specialit.* 2015;3:64.
9. Sadhwani BS, Anchlia S. Conventional 2.0 mm miniplates versus 3-D plates in mandibular fractures. *Ann Maxillofac Surg.* 2016;3:154-59.
10. Malhotra K, Sharma A, Giraddi G, Shahi AK. Versatility of titanium 3D plate in comparison with conventional titanium miniplate fixation for the management of mandibular fracture. *J Maxillofac Oral Surg.* 2012;11:284-90.
11. Siddiqui FI, Naphade MV, Naphade UM, Adwani DG, Shroof PR, Anwar SS. Management of anterior mandibular fractures using two different fixation methods. *J Craniofacial Sci.* 2016;4:4-9.
12. Patel MAR, Rathod MAS, Haneef M. comparison of 2D vs 3D miniplates in the management of anterior mandibular fractures- a comparative study. *Rughs Med Sci.* 2016;6:66-70.
13. Farmand M, Dupoirieux L. The value of 3-dimensional plates in maxillofacial surgery. *Rev Stomatol Chir Maxillofac.* 1992;93: 353-7.
14. Zix J, Lieger O, Iizuka T. Use of straight and curved 3-dimensional titanium miniplates for fracture fixation at the mandibular angle. *J Oral Maxillofac Surg.* 2007;65:1758-63.
15. Zafar KJ, Khurram M, Janjua OS, Saleh MI, Khalid S, Khali MU, Ahmed R. Comparison of three-dimensional plates versus conventional two miniplates for open reduction and internal fixation of mandibular symphysis and parasymphysis fractures. *APMC.* 2019;13(1):51-5.
16. EL Nakeeb, EL Dibany, Shokry MM. A comparative study between 3-d plates and conventional miniplates for internal fixation of anterior mandibular fractures. *Alexandria Dental Journal.* 2016;41:253-260.
17. Gokkulakrishnan S, Singh S, Sharma A, Shahi AK. An analysis of postoperative complications and efficacy of 3-D miniplates in fixation of mandibular fractures. *Dent Res J.* 2012;9(4):414-21.
18. Al-Tairi NH, Shoushan MM, Khedr MS, Abd-alal SE. Comparison of three-dimensional plate versus double miniplate osteosynthesis for treatment of unfavorable mandibular angle fractures. *Tanta Dental Journal.* 2015;12(2):89-98.
19. Kumar BP, Kumar J, Mohan AP, Venkatesh V, Kumar R. A comparative study of three-dimensional stainless-steel plate versus stainless steel miniplate in the management of mandibular parasymphysis fracture. *J Bio Innov.* 2012;1(2):19-32.
20. Kinra PK, Jayakumar K, Soumithran CS, Michael MJ, Passi D, Singh M. Comparative evaluation of bite force analytical study following mandibular osteosynthesis using three-dimensional and conventional locking miniplates. *Natl J Maxillofac Surg.* 2017;8(1):34-40.
21. Kishor K, et al. The efficacy of three dimensional miniplate versus standard miniplate in fixation of anterior mandibular fracture: A comparative study. *Acta Scientific Dental Sciences.* 2019;3(6): 14-19.

© 2020 Kumari et al.; This is an Open Access article distributed under the terms of the Creative Commons Attribution License (<http://creativecommons.org/licenses/by/4.0>), which permits unrestricted use, distribution, and reproduction in any medium, provided the original work is properly cited.

Peer-review history:
The peer review history for this paper can be accessed here:
<http://www.sdiarticle4.com/review-history/63824>