

# Bifurcated Arc of Buhler Co-existent with an Arc of Riolan-A Rare Case Report

HARSHA PRATAP<sup>1</sup>, SARAH RAMAMURTHY<sup>2</sup>

(CC) BY-NC-ND

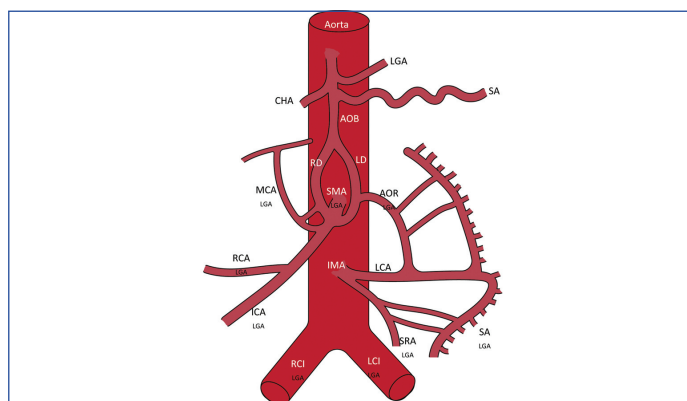
## ABSTRACT

The Arcs of Buhler and Riolan are collateral channels that connect the major midline ventral branches of the abdominal aorta, which supply the gastrointestinal tract. These arcs occur with a relative rarity of 1-10%. During routine dissection of the abdominal cavity of a 50-year-old, embalmed male Indian cadaver in the Department of Anatomy of a National Institute in South India, the presence of a large vertical tortuous bifurcated artery was noticed, posterior to the body of the pancreas, connecting the coeliac trunk to the superior mesenteric artery. This was identified to be an Arc of Buhler (AOB) and measuring 8 mm in external diameter. In addition, an Arc of Riolan (AOR) was identified, connecting the left division of the Buhler's arc to the left colic artery. The presence of a large bifurcated AOB or its co-existence with an AOR has not been described previously. The identification of such anastomotic channels in symptomatic patients may help in diagnosing impending bowel ischemia. Aneurysms of AOB, though rare, are life-threatening and have been treated successfully. The knowledge of mesenteric vasculature is important during abdominal surgeries and endovascular procedures. Recognising a vascular variation is crucial to avoid inadvertent bleeding or bowel ischaemia.

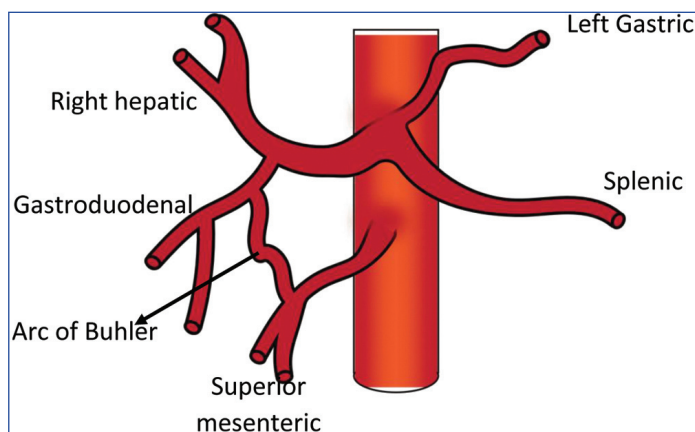
**Keywords:** Abdomen, Collateral circulation, Mesenteric vasculature

## CASE REPORT

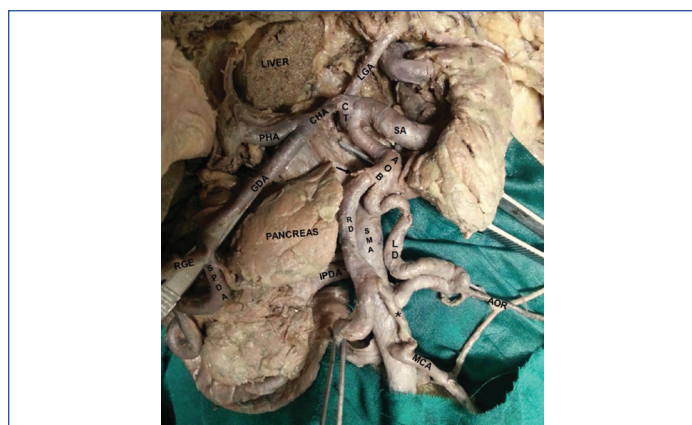
During the routine dissection of a 50-year-old, male, embalmed cadaver in the Department of Anatomy, the following anatomical variations were observed. The length of the vessels and their external diameter were measured using a measuring tape and Vernier calipers, respectively. The coeliac artery gave rise to four branches. The left gastric artery, the splenic artery, and the common hepatic artery were the conventional branches [Table/Fig-1]. A fourth branch was a tortuous Arc of Buhler (AOB) with an external diameter of 8.4 mm. It descended vertically in the midline, posterior to the body of the pancreas, and bifurcated into two divisions: the right and left, each of which communicated with the corresponding surfaces of the main trunk of the Superior Mesenteric Artery (SMA), distal to the origin of the inferior pancreaticoduodenal artery. The external diameter of the right and left divisions was 8 mm and 7.2 mm, respectively. The right division of the AOB was found to anastomose with the middle colic artery by a 2.4 cm long branch [Table/Fig-1a-c]. A small branch from the right division of the AOB was traced to the body of the pancreas. The pancreaticoduodenal arcades supplying the head of the pancreas were tortuous, though typical in origin and location.



**[Table/Fig-1b]:** Diagrammatic representation of the dissected specimen. CT- Celiac Trunk, LGA-Left Gastric Artery, SA-Splenic Artery, CHA-Common Hepatic Artery, PHA-Proper Hepatic Artery, GDA-Gastro Duodenal Artery, RGEA- Right Gastro Epiploic Artery, SPDA-Superior Pancreatico-Duodenal Artery, IPDA- Inferior Pancreatico Duodenal Artery, AOB-Arc Of Buhler, RD- Right Division of AOB, LD-Left Division of AOB, SMA-Superior Mesenteric Artery, MCA-Middle Colic Artery, \*communicating branch between RD of AOB and MCA, AOR-Arc Of Riolan



**[Table/Fig-1c]:** Diagrammatic representation of Arc of Buhler for comparison.

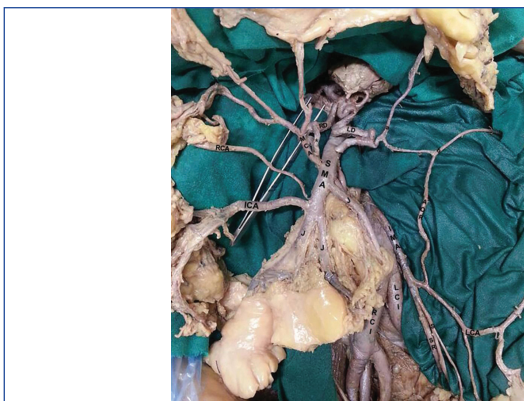


**[Table/Fig-1a]:** Dissected specimen of bifurcated Arc of Buhler co-existent with Arc of Riolan.

An arterial arcade, AOR, connected the left division of AOB to the proximal part of the left colic artery (branch of Inferior Mesenteric

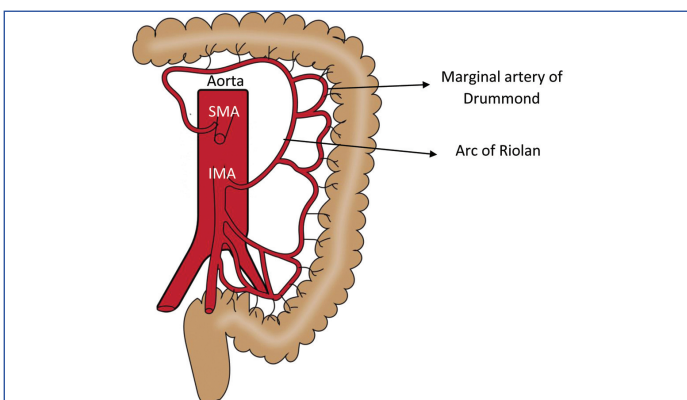
Artery (IMA) [Table/Fig-2a,b]. It measured 13 cm in length and 3 mm in external diameter. The AOR had two branches that took part in the formation of the Marginal artery of Drummond, close to the mesenteric border of the distal one-third of the transverse colon and upper one-third of descending colon.





**[Table/Fig-2a]:** Dissected specimen of Arc of Rioloan.

SMA-Superior Mesenteric Artery, MCA-Middle Colic Artery, RD- Right Division of AOB, LD- Left Division of AOB, RCA-Right Colic Artery, ICA-Ileo-Colic Artery, J- Jejunal branch of SMA, AOR-Arc Of Rioloan, a & b- branches of AOR, IMA- Inferior Mesenteric Artery, LCA-Left Colic Artery, S- sigmoid branch of IMA, SR- Superior Rectal Artery, LCI- Left Common Iliac artery, RCI- Right Common Iliac artery



**[Table/Fig-2b]:** Diagrammatic representation of Arc of Rioloan for comparison.

## DISCUSSION

Three midline ventral branches of the abdominal aorta: the coeliac trunk (CT), the SMA and the IMA supply the gastrointestinal tract, from the distal third of the oesophagus to the upper third of the anal canal [1]. Largely constant interconnecting collateral circulations such as the anterior and posterior pancreaticoduodenal arcades, Kirk's arcade, and the Marginal Artery of Drummond exist between these vessels in order to reinforce the arterial supply to the gut and related organs [1, 2].

A few collateral pathways occur with relative rarity. The AOB (AOB) is one such vertical unpaired artery anastomosing the CT and the SMA [3]. The AOR, also called as the Meandering mesenteric artery, is described as an anastomosing vessel between the SMA or its branches and the IMA [1]. The AOB was originally described in 1904 as a communication between the CT and a branch of the middle colic artery but has been reported to proximally connect to the splenic branch of the CT or distally to the SMA [3,4]. Existing literature states its incidence varies between 1-4% [3,5]

The knowledge of such vascular anatomy is important during abdominal surgeries and endovascular procedures [3,6]. Recognising a vascular variation is crucial to avoid inadvertent bleeding or bowel ischaemia [7].

In the present case, the AOB was connected proximally to the coeliac trunk. Distally, it bifurcated posterior to the body of the pancreas, and these divisions anastomosed with the main trunk of SMA. Such a bifurcated AOB has not been reported previously. With respect to the vessel diameter, the maximum internal diameter of the AOB has been reported to measure less than 2.5 mm [8]. In the present case, though we only measured the external diameter of the AOB, it was considerably large (8 mm). The presence of large vessels posterior to the body of the pancreas is unexpected during

abdominal surgeries [6,9]. It mandates prior knowledge and careful dissection and preservation when found.

Though the presence of AOR and AOB was reported individually, the presence of two coexistent mesenteric anastomosing channels in the same patient, such as an AOB and AOR, has also not been reported previously. In the present case, the AOR has been identified by a) the location of the arcade close to the root of the mesentery b) an already existing marginal artery formed in part by the arcade's two branches and c) the arcade's connection to the SMA. The presence of an AOR has been found to be useful to diagnose impending bowel ischaemia [7,10,11].

The anatomy of mesenteric vasculature and its variations are important to surgeons performing abdominal surgeries, particularly those involving the pancreas, stomach, liver, duodenum, and colon [2,12]. The evaluation of the diameter of AOB and AOR is important in procedures involving vessel ligation, resection or embolisation [8]. Aneurysms of AOB, though rare, are life-threatening and have been treated successfully by trans-arterial coil embolisation [13,14]. The preservation of collateral channels once detected during surgery avoids inadvertent causation of bleeding or ischaemic bowel necrosis [3]. Rarely, variations of abdominal vasculature may present with symptoms of chronic abdominal pain or jaundice [15,16].

## CONCLUSION(S)

Knowledge of mesenteric vasculature and its variations is important to surgeons performing abdominal surgeries, particularly those involving the pancreas, stomach, liver, duodenum, and colon to avoid inadvertent bleeding during surgical procedures. This case report supplements current knowledge on possible variations in mesenteric vasculature, which could be encountered in clinical practice.

## REFERENCES

- [1] Standring S, ed (2008). Gray's Anatomy: The Anatomical Basis of Clinical Practice. Edinburgh, London.
- [2] Walker TG. Mesenteric vasculature and collateral pathways. Semin Intervent Radiol. 2009; 26 (3):167-74.
- [3] McNulty JG, Hickey N, Khosa F, O'Brien P, O'Callaghan JP. Surgical and radiological significance of variants of Böhler's anastomotic artery: A report of three cases. Surg Radiol Anat. 2021;23 (4):277-80.
- [4] Prasanna LC, Alva R, Sneha GK, Bhat KM. Rare variations in the origin branching pattern and course of the celiac trunk: Report of two cases. Malays J Med Sci. 2016;23(1):77-81.
- [5] Grabbe E, Bücheler E. Die Böhlersche Anastomose. Rofo. 1980;132(5):541-46. doi: 10.1055/s-2008-1056615.
- [6] Michailinos A, Schizas D, Ntourakis D, Filippou D, Troupis T. Arc of Böhler: the surgical significance of a rare anatomical variation. Surg Radiol Anat. 2019;41(5):575- 81. doi: 10.1007/s00276-018-2168-0. Epub 2018 Dec 14. PMID:30552487.
- [7] Xie Y, Jin C, Zhang S, Wang X, Jiang Y. CT features and common causes of arc of Rioloan expansion: an analysis with 64-detector-row computed tomographic angiography. Int J Clin Exp Med. 2015; 8(3):3193-201.
- [8] Saad WE, Davies MG, Sahler L, Lee D, Patel N, Kitanosono T et al. Arc of Buhler: incidence and diameter in asymptomatic individuals. Vasc Endovascular Surg. 2005; 39(4):347-49.
- [9] Kageyama Y, Kokudo T, Amikura K, Miyazaki Y, Takahashi A, Sakamoto H. The arc of Buhler: special considerations when performing pancreaticoduodenectomy. Surg Case Rep. 2016;2(1):21. doi: 10.1186/s40792-016-0149-2. Epub 2016 Mar 7. PMID: 26951124; PMCID: PMC4781825.
- [10] Lange JF, Komen N, Akkerman G, Nout E, Horstmannshoff H, Schlesinger F, et al. Rioloan's arch: confusing, misnomer, and obsolete. A literature survey of the connection(s) between the superior and inferior mesenteric arteries. Am J Surg. 2007;193(6):742-48.
- [11] McCracken E, Turley R, Cox M, Suhocki P, Blazer DG 3rd. Leveraging aberrant vasculature in celiac artery stenosis: The Arc of Buhler in pancreaticoduodenectomy. J Pancreat Cancer. 2018;4(1):4-6.
- [12] Ochoa JE, Pointer DT Jr, Hamner JB. Vascular Anomalies in pancreaticoduodenectomy: A lesson learned. Case Rep Surg. 2016;2016:5792980.
- [13] Jeong SJ, Lim NY, Jang NK, Choi SJ, Kim JK, Jeong YY, Kang HK. Transcatheter coil embolization of an Arc of Buhler aneurysm. Korean J Radiol. 2008;9 Suppl(Suppl):S77-80. doi: 10.3348/kjr.2008.9.s.s77. PMID: 18607134; PMCID: PMC2627200.
- [14] Gregory J. Dubel, Sun Ho Ahn, M. Ali Saeed. Interventional management of Arc of Buhler aneurysm. Semin Intervent Radiol. 2007; 24(1): 76-81.



- [15] Jayia P, Hosney S, Subramanian A, Onnie C. Arc of Buhler aneurysm: A rare cause of obstructive jaundice. Vasc Endovascular Surg. 2011;45(1):92.
- [16] Baz RO, Scheau C, Baz RA, Niscoveanu C. Buhler's Arc: an unexpected finding in a case of chronic abdominal pain. J Gastrointest Liver Dis. 2020;20(3):304.

**PARTICULARS OF CONTRIBUTORS:**

1. Core Surgical Trainee, Department of Surgery, North West School of Surgery, Manchester, United Kingdom.
2. Assistant Professor, Department of Anatomy, AIIMS Mangalagiri, Andhra Pradesh, India.

**NAME, ADDRESS, E-MAIL ID OF THE CORRESPONDING AUTHOR:**

Sarah Ramamurthy,  
Department of Anatomy, First Floor, Medical College Building AIIMS Mangalagiri,  
Andhra Pradesh, India.  
E-mail: sarah@aiimsmangalagiri.edu.in

**PLAGIARISM CHECKING METHODS:** [Jain H et al.]

- Plagiarism X-checker: Aug 16, 2022
- Manual Googling: Oct 17, 2022
- iThenticate Software: Oct 19, 2022 (20%)

**ETYMOLOGY:** Author Origin**AUTHOR DECLARATION:**

- Financial or Other Competing Interests: None
- Was informed consent obtained from the subjects involved in the study? NA
- For any images presented appropriate consent has been obtained from the subjects. NA

Date of Submission: **Aug 11, 2022**Date of Peer Review: **Sep 19, 2022**Date of Acceptance: **Oct 20, 2022**Date of Publishing: **Jan 01, 2023**